

# BRVO Case Illustrates Safety and Efficacy of MicroPulse® for Fovea-Involving Macular Edema



**David D. Gossage, DO, FAOCO, FAAO,** is Medical Director of the Gossage Eye Institute in Hillsdale, Mich. He is also a Clinical Associate Professor of Ophthalmology at Michigan State University in East Lansing.

At the time I purchased the IRIDEX IQ 532™ laser for my comprehensive ophthalmology practice, my main goal was to replace the water-cooled argon laser I'd been using with a versatile solid-state laser. I wanted to be able to utilize my new device for both glaucoma and retina applications as I have been doing, and the green-wavelength IQ 532 laser fulfilled that primary requirement. Eventually, I also began to take advantage of the laser's capability to provide MicroPulse Laser Therapy for retina and glaucoma applications. Having MicroPulse and continuous-wave (CW) treatment options in one unit makes the IQ 532 a very versatile laser system that also saves the practice space and expense compared with purchasing and housing multiple lasers.

I consider MicroPulse a viable option for treating macular edema associated with just about any retina condition for which I would have used CW laser in the past — with the welcome addition of edema that involves the fovea. A substantial body of literature shows that MicroPulse is as effective as conventional CW thermal laser for treating a number of retinal conditions, but without producing collateral tissue damage.<sup>1-3</sup> While the 810-nm wavelength for MicroPulse has been studied most extensively, other evidence and physician experience to date indicate the 577-nm and 532-nm wavelengths are just as safe and effective.<sup>4-6</sup> Depending on what condition I'm treating and on individual patient characteristics, I may use MicroPulse as first-line monotherapy or in combination with other treatments. In diabetic macular edema, for example, I often follow a few anti-VEGF injections with MicroPulse in order to reduce or eliminate the need for future injections, saving patients time and costs. Here I describe a case of branch retinal vein occlusion (BRVO) in which I would have been unwilling to use conventional laser for

treating near the fovea, but standalone MicroPulse resolved the patient's center-involving macular edema.

## CHRONIC BRANCH RETINAL VEIN OCCLUSION

The patient was first diagnosed with BRVO in the left eye in April 2009 when she was 79 years old. During that visit, central retinal thickness (CRT) was 309 μm and VA was 20/30. Following conventional wisdom, which leaned toward observation rather than treatment unless VA was 20/40 or worse, and the fact that the patient preferred not to undergo treatment, the decision was made to monitor the condition. The patient had a history of age-related macular degeneration (AMD), but that had no bearing on the decision.

The patient returned on May 2, 2014, describing that she was experiencing metamorphopsia and reporting that her vision had become worse. Her VA that day was the same as in April 2009, 20/30, and CRT was less at 263 μm. However, OCT showed extrafoveal thickness had increased from 288 μm to 321 μm, and juxtafoveal thickness measured 352 μm. (Figure 1A) On clinical exam, I could see the edema was encroaching into the macula and fovea.

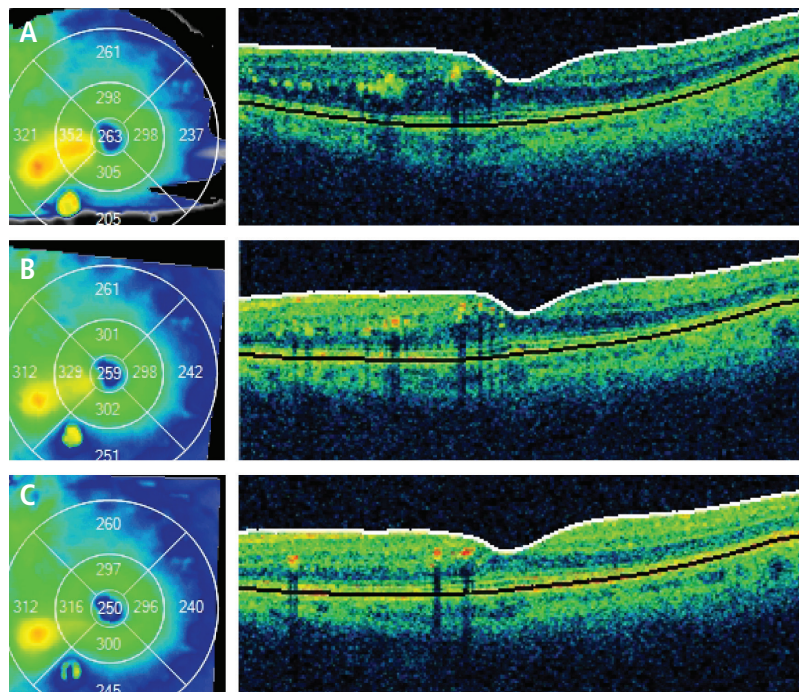


Figure 1. (A) May 2, 2014 | Prior to MicroPulse | CRT 263 μm | VA 20/30, (B) June 16, 2014 | 6 weeks post MicroPulse | CRT 259 μm | VA 20/30, (C) Aug. 20, 2014 | 15 weeks post MicroPulse | CRT 250 μm | VA 20/25.

*“I consider MicroPulse a viable option for treating macular edema associated with just about any retina condition for which I would have used CW laser in the past — with the welcome addition of edema that involves the fovea.”*

#### TXCELL-GUIDED MICROPULSE LASER THERAPY

I explained to the patient that it was very unlikely the macular edema would resolve on its own given the chronicity of the BRVO, and she agreed to be treated with MicroPulse. Now that I’m experienced using MicroPulse, I usually don’t perform a CW test burn prior to the procedure, and I didn’t in this case. I have found 300 mW of power works well in moderately thickened retinas, and up to 400 mW is effective for substantially thickened retinas.

In this case, I used 300 mW of power, 200-ms duration and 5% duty cycle and applied 245 confluent 200- $\mu$ m spots. I used the IRIDEX TxCell™ Scanning Laser Delivery System to place the spots in five 7x7 treatment grids covering all areas of edema, including over the fovea. (Table 1) Multi-spot pattern delivery with TxCell is much more efficient than single-spot placement, which is an advantage for me and the patient.

The patient returned for follow-up on June 16, 2014, 6 weeks after MicroPulse. At this visit, VA was still 20/30, but CRT decreased to 259  $\mu$ m, juxtafoveal thickness decreased to 329  $\mu$ m and extrafoveal thickness decreased to 312  $\mu$ m. (Figure 1B) Because anatomic improvements were occurring, and the patient felt her vision was stable, no treatment was given. She returned for her next follow-up visit approximately 9 weeks later on Aug. 20, 2014. At that time, the patient reported her vision was better. Examination revealed that her VA had indeed improved to 20/25, and CRT also improved to 250  $\mu$ m. OCT showed the central and juxtafoveal macular edema to be completely resolved, and the amount of exudate was noticeably reduced. (Figure 1C) Some residual extrafoveal edema remained, but may further improve over time.

#### CONTINUED IMPROVEMENT EXPECTED

When I wrote the description of this case, the patient was 16 weeks post MicroPulse. Her retinal anatomy as well as her symptoms and vision had improved. Based on my experience, I would not be surprised if she improved further in subsequent months, although her AMD may preclude 20/20 vision. I have seen gradual, continued improvement in patients 3 to 6 months and even a year after MicroPulse. If macular edema recurs in this particular patient and she becomes symptomatic during that approximate timeframe, I wouldn’t hesitate to treat her again with MicroPulse. Repeat treatment has been safe and effective for many of my patients. ■

**Table 1. TREATMENT PARAMETERS**

IQ 532 with TxCell-guided MicroPulse for ME due to BRVO

- Wavelength: 532 nm
- Spot size on slit lamp adapter: 200  $\mu$ m
- Contact lens: standard (no high magnification) Volk
- Power: 300 mW
- Exposure duration: 200 ms
- Duty cycle: 5%
- TxCell-guided MicroPulse Delivery: High-density, confluent application of 245 spots in five 7x7 treatment grids to cover all areas of retinal thickening, including over the fovea.

#### REFERENCES

1. Vujosevic S, Bottega E, Casciano M, et al. Microperimetry and fundus autofluorescence in diabetic macular edema: subthreshold micropulse diode laser versus modified early treatment diabetic retinopathy study laser photocoagulation. *Retina* 2010;30(6):908-916.
2. Lavinsky D, Cardillo JA, Melo LA Jr, et al. Randomized clinical trial evaluating mETDRS versus normal or high-density micropulse photocoagulation for diabetic macular edema. *Invest Ophthalmol Vis Sci* 2011;52(7):4314-4323.
3. Gupta B, Elagouz M, McHugh D, et al. Micropulse diode laser photocoagulation for central serous chorio-retinopathy. *Clin Experiment Ophthalmol* 2009;37(8):801-805.
4. Yadav NK, Jayadev C, Rajendran A, Nagpal M. Recent developments in retinal lasers and delivery systems. *Indian J Ophthalmol*. 2014;62(1):50-54.
5. Yu AK, Merrill KD, Truong SN, et al. The comparative histologic effects of subthreshold 532- and 810-nm diode micropulse laser on the retina. *Invest Ophthalmol Vis Sci*. 2013;54(3):2216-2224.
6. Vujosevic S, Martini F, Convento E, et al. Subthreshold laser therapy for diabetic macular edema: metabolic and safety issues. *Curr Med Chem*. 2013;20(26):3267-3271.



To learn more about MicroPulse, go to [www.iredex.com/micropulse](http://www.iredex.com/micropulse)

Treatment techniques and opinions presented in this case report are those of the author. IRIDEX assumes no responsibility for patient treatment and outcome. IRIDEX, IRIDEX logo and MicroPulse are registered trademarks, TxCell and IQ 532 are trademarks of IRIDEX Corporation.

IRIDEX | 1212 Terra Bella Avenue | Mountain View, CA 94043 | 800.388.4747 (U.S. inquiries) | info@iredex.com (U.S. & int'l inquiries) | www.iredex.com

© 2014 IRIDEX Corporation. All rights reserved. LT610