



TECHNICAL TALK

MICROPULSE TRANSSCLERAL LASER THERAPY AFTER TUBE SHUNT SURGERY



This management option yields a quick recovery time and carries minimal risk of hypotony.

BY BRIAN M. JERKINS, MD

When traditional topical and oral medications fail to control IOP, clinicians often elect to place a glaucoma drainage implant. Although effective, tube shunt implantation may be associated with serious complications and failure rates of around 33% after 3 years, according to the Primary Tube Versus Trabeculectomy Study.¹ Several factors can influence the success of tube shunt surgery, including fibrosis and patient compliance with topical steroids.²

However, in the event that an aqueous drainage implant fails, the primary question is: What do I do next? In this scenario, the clinician must first determine if the shunt is truly deficient and then decide on a management plan. Management options include revising or replacing the original implant, placing a second tube shunt (usually in the opposite quadrant), or performing MicroPulse cyclophotocoagulation (Iridex).

The literature is sparse regarding acceptable treatment modalities after primary tube shunt failure. Most practitioners elect to place a second implant, despite a reported 60% failure rate after 3 to 6 years.³ Placement of a secondary shunt may put a patient at risk for extensive hypotony, larger conjunctival dissections, bleeding, and a longer recovery time. Although long-term complications may be seen with primary tube shunts, they are especially prominent with secondary implants and can include endothelial cell loss, diplopia, and shunt erosion.⁴

I have used every management option listed above and have found problems with each mode of treatment. In revising a shunt, I dissect down to the original implant and remove as much pseudocapsule as possible without disrupting the original implant. I then reapproximate the conjunctiva. In my hands, revisions work about 50% of the time. With placement of a second tube shunt, I

have found that patients require close follow-up and that the recovery time is long and tenuous compared with that after transscleral laser therapy. I have subsequently turned to MicroPulse transscleral laser therapy to manage shunt failure, given its associated short recovery times, easy postoperative care, and high success rate.

MICROPULSE: AN ALTERNATIVE

MicroPulse is an option that mitigates the aforementioned risks of tube shunt implantation or revision. With a quick recovery time (a few days to a week at most) and minimal risk of hypotony, this treatment is a safe and effective alternative to placing a second implant. Although I have observed some transient hypotony following tube shunt implantation, I have not yet experienced postoperative hypotony with MicroPulse ablation.⁵

Patients typically tolerate the MicroPulse treatment well. We perform all procedures at our surgery center under monitored propofol sedation. We administer enough propofol to the patient for 5 to 10 minutes of twilight sleep, which is normally adequate time for me to perform the procedure.

It is important to remember that postoperative results are dependent on correct probe placement, which can be greatly affected by lid squeezing or grimacing by the patient (Figure). During

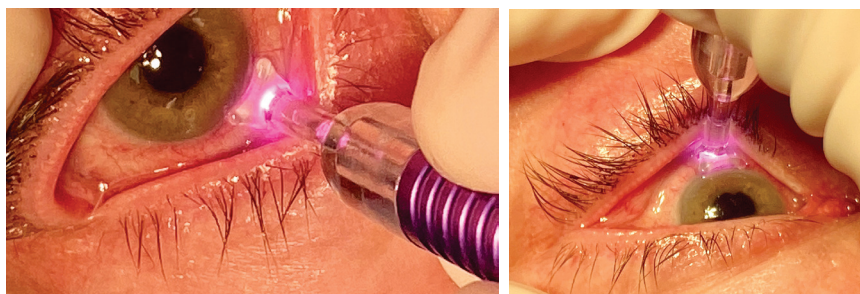


Figure. Postoperative results of MicroPulse therapy are dependent on correct probe placement.

induction, I usually give light retrobulbar anesthesia, or peribulbar anesthesia for patients on blood thinners, to mitigate these movements. I then start treatment with these standard settings: 2,000 mW of 810-nm infrared diode laser set on MicroPulse delivery mode, five passes of 16 seconds each per hemisphere, and 31.3% duty cycle.⁶ I use lidocaine gel to help couple the probe to the globe (a coupling agent is essential for proper coupling of delivery device to tissue).

Once the procedure is completed, I apply dexamethasone/neomycin sulfate/polymyxin B sulfate ointment and place a pressure patch on the eye, which the patient is instructed to remove after 3 hours. I manage any inflammation with topical NSAIDs for about 1 week, as inflammation is usually minimal and I want to avoid steroid-induced IOP spikes.

Patients sometimes experience mild dry eye or soreness, but nine times out of 10 they have no complaints. I usually instruct patients to stop oral acetazolamide prior to MicroPulse treatment but

to continue any topical drops perioperatively. This enables me to adjust one parameter at a time and evaluate the laser treatment effect.

CASE SERIES

In a series of 16 patients treated with MicroPulse in my clinic after failed tube shunt placement over the past 2 years, we have seen encouraging results. Preoperative mean IOP of 23.25 mm Hg (range, 17–30 mm Hg) was decreased to a mean 14.0 mm Hg (range, 6–18 mm Hg) at 3 months. Approximately 87% of patients with a failed tube shunt who underwent MicroPulse therapy achieved a greater than 20% reduction in IOP, with 62.5% achieving an IOP reduction of greater than 30% (range, 0%–80%). Number of medications decreased from 3.5 (range, 5.0–3.0) preoperatively to 2.1 (range, 0.0–4.0) at 3 months after treatment.

CONCLUSION

Treatment options after failed tube shunt implantation are limited.

MicroPulse therapy shows promise for surgeons who wish to avoid further invasive procedures. It also works well in tandem with tube shunt implants before primary implantation. Overall, the procedure is straightforward and fast, with an easy recovery and minimal complication rates. ■

1. Gedde SJ, Feuer WJ, Lim KS, et al; for the Primary Tube Versus Trabeculectomy Study Group. Treatment outcomes in the Primary Tube Versus Trabeculectomy (PTVT) study after three years of follow-up. *Ophthalmology*. 2020;127(30):333–345.
2. Tseng VL, Coleman AL, Chang MY, Caprioli J. Aqueous shunts for glaucoma. *Cochrane Database Syst Rev*. 2017;7:CD004918.
3. Schaefer JL, Levine MA, Martorana G. Failed glaucoma drainage implant: long-term outcomes of a second glaucoma drainage device versus cyclophotocoagulation. *Br J Ophthalmol*. 2015;99(12):1718–1724.
4. Chen J, Gedde SJ. New developments in tube shunt surgery. *Curr Opin Ophthalmol*. 2019;30(2):125–131.
5. Chen MF, Kim CH, Coleman AL. Cyclodestructive procedures for refractory glaucoma. *Cochrane Database Syst Rev*. 2019;3:CD012223.
6. Kuchar S, Moster MR, Reamer CB. Treatment outcomes of MicroPulse transscleral cyclophotocoagulation in advanced glaucoma. *Lasers Med Sci*. 2016;31(2):393–396.

BRIAN M. JERKINS, MD

- Glaucoma Specialist, Hamilton Eye Institute, Nashville, Tennessee
- Assistant Professor of Ophthalmology, University of Tennessee Health Science Center
- bjerkins@uthsc.edu
- Financial disclosure: Lecture fees (Iridex)