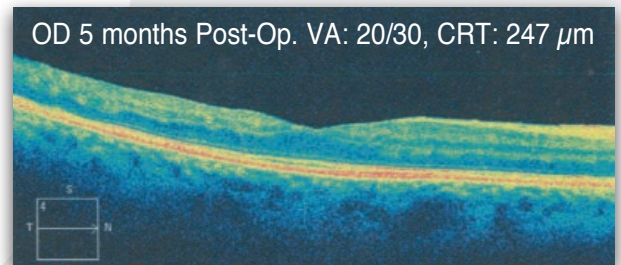
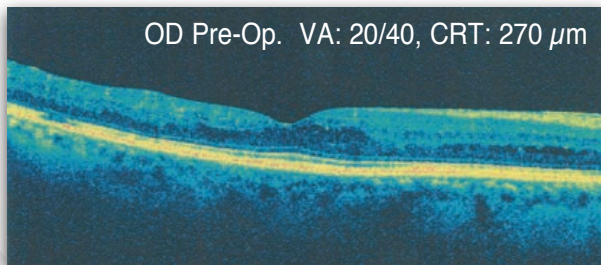




MicroPulse™ Case Report

First, do no harm

DME - First Line Therapy | IQ 532™



Physician: Aaron Appiah, MD | Tallahassee, FL

Patient: 70-year-old, white female with longstanding DM, new onset DME. OD edema above macula extending into nasal fovea.

MicroPulse Treatment Parameters

Laser | Wavelength: IQ 532 | 532 nm

Spot Size on SLA: 100 μm

Contact Lens: Mainster Focal Grid

Power: 450 mW*

Duration: 200 ms

Duty Cycle: 5%

Evidence of Laser Treatment on FA: None

Physician Technique: 352 laser applications delivered in a dense, contiguous pattern over the edematous area based on OCT.

*Based on 4x the power determined from a pre-treatment test burn performed in continuous-wave mode in a non-edematous area of the retina. Start at 50 mW and titrate power up by increments of 10 mW (moving to different locations) until a barely visible burn is achieved.

Treatment techniques and opinions presented in this case report are those of the author. IRIDEX assumes no responsibility for patient treatment or outcome.



IRIDEX

Elegantly simple solutions™