

## MicroPulse™ Laser Therapy of Diabetic Macular Edema Success in Anti-VEGF Non-responder



**Sam E. Mansour, MSc, MD, FRCS(C), FACS**, is Medical Director of the Virginia Retina Center in Warrenton, Va., and Clinical Professor of Ophthalmology at the George Washington University School of Medicine in Washington, D.C. Contact him at [sm@virginiaretina.com](mailto:sm@virginiaretina.com) or (703) 443-0015.

### History and examination

A 69-year-old woman with Type 2 diabetes mellitus was referred to our clinic after being treated unsuccessfully elsewhere. Her records indicated a three-year history of clinically significant diabetic macular edema (CSDME). She already had received multiple injections of intravitreal bevacizumab (Avastin, Genentech) and triamcinolone in both eyes, with little or very transient effect. Her left eye also had received focal laser treatment.

Upon examination, the laser-treated left eye had minimal edema but was the worse-seeing eye (20/80<sup>-2</sup>) due to laser-induced scotomas. The patient was very unhappy about her decreased vision and had refused subsequent laser treatment in the other eye because of her dissatisfaction. In the dominant right eye, optical coherence tomography (OCT) and fluorescein angiography (FA) revealed clinically significant macular edema (Figs 1, 2). Central retinal thickness was 326  $\mu\text{m}$  and visual acuity (VA) was 20/50<sup>-1</sup>.

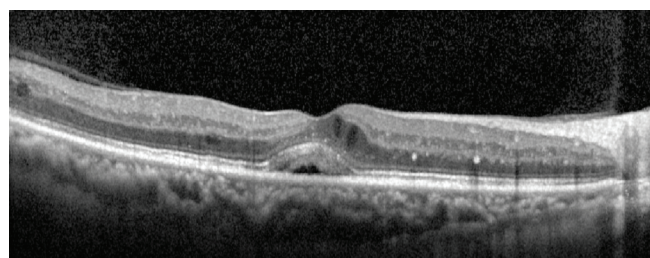


Figure 1. Pre-MicroPulse Laser Treatment: SD-OCT (Spectralis) CSDME Right Eye. Central retinal thickness: 326  $\mu\text{m}$ .

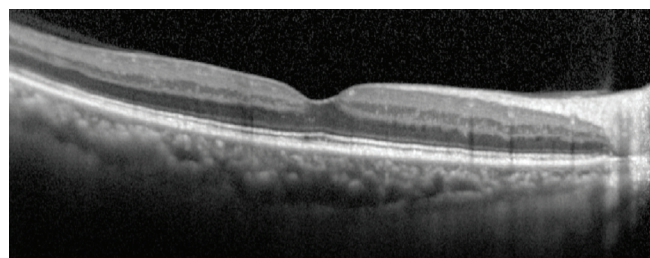


Figure 3. 6 Weeks Post-MicroPulse Treatment: Central retinal thickness: 272  $\mu\text{m}$

### Tissue-Sparing Treatment

This patient had to be convinced to undergo a different type of laser therapy. In July, I treated the right eye with the IRIDEX IQ 577™ laser.

First, I used the laser in continuous-wave (CW) mode to very lightly cauterize a few microaneurysms. To determine the power for the MicroPulse™ laser therapy, I performed a CW test burn in a non-edematous area of the retina, outside the vascular arcade with a 100  $\mu\text{m}$  spot. I typically start at 100 mW and slowly increase the power by 50-mW increments until I get a barely visible burn. I double that power setting when I switch to MicroPulse mode for the subvisible (no endpoint), confluent grid treatment. Typically, MicroPulse power ranges from 200-800 mW. In this case, I used 500 mW at a 5% duty cycle and 200-ms duration (Table 1).

### Immediate Result

The patient was seen for follow-up 6 weeks after treatment. After just the single treatment, there was a significant reduction in the retinal thickness, from 326  $\mu\text{m}$  to 272  $\mu\text{m}$ . As expected, there is no scarring or other visible sign of the laser spots (Figs 3, 4). Although the edema was not completely resolved, the VA improved by 2 lines, from 20/50<sup>-1</sup> to 20/25<sup>-2</sup>. The patient was pleased with the visual improvement. At a second follow-up 6 weeks later, the edema continued to resolve so we have not yet repeated the laser or given any additional Avastin injections.

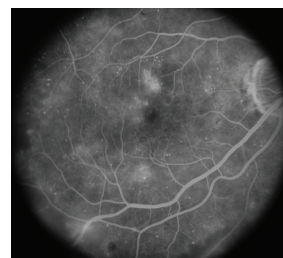

Figure 2. Pre-MicroPulse Laser Treatment: FA CSDME Right Eye. VA: 20/50<sup>-1</sup>

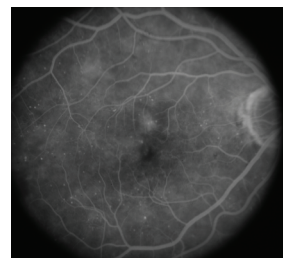

Figure 4. 6 Weeks Post-MicroPulse Treatment: VA: 20/25<sup>-1</sup>

### Discussion and treatment pearls

In my experience with MicroPulse, the visual improvement is often out of proportion with respect to reduction in retinal thickness, as was the case with this patient. Certainly, there are different therapeutic mechanisms involved compared to conventional laser photocoagulation. Rather than causing cellular destruction, MicroPulse therapy uses laser light to photostimulate the retinal pigment epithelium (RPE) cells to balance the expression of biochemical factors that result in overall amelioration of the diabetes-induced vascular damage.

In addition to its MicroPulse capability, the IRIDEX IQ 577 laser was appealing to me because I can use it in CW mode to perform any other conventional procedure, from microaneurysm ablation to laser retinopathy. The yellow 577-nm wavelength is very safe for treating the macula because it is absorbed by the RPE, but not by the xanthophyll pigment in the fovea. If you have to pick one laser wavelength, I feel that 577-nm yellow light provides the greatest versatility and the best safety profile.

I do think it is important to spend some time educating patients—especially when they have had a previous laser experience—about what to expect from MicroPulse laser therapy. I tell patients they may need two to three treatments over several months, but that the end result will be a more significant and longer lasting improvement in vision with fewer side effects than any other treatment option currently available. In this case, no additional laser treatment was necessary at 3 months follow-up.

### Role of MicroPulse™ in my practice

There have been several recent innovations in laser therapy. PASCAL, for example, is designed to quickly deliver a pattern of sequential laser spots. While useful, especially for pan-retinal photocoagulation, the treatment endpoint is still a burn. Conversely, MicroPulse technology modifies the CW laser energy in a train of on/off pulses that allows for thermal relaxation of the tissue during the “off” portion to avoid creating a thermo-destructive burn.

I admit that I was initially very skeptical of MicroPulse, considering it almost a “homeopathic” laser because of the lack of a visible endpoint. But with increasing evidence of its efficacy in the literature, I think we are all realizing that defining a therapeutic endpoint by the proportion of charred retina is actually quite primitive. We can now rely on objective VA, OCT, and FA to assess the efficacy of laser treatment, and the results have been excellent with no laser burns and collateral effects.

In my practice: MicroPulse has now completely replaced conventional laser for macular edema resulting from diabetes or retinal vein occlusion, and what remains to be explored is the optimal regimen of bevacizumab and triamcinolone that can be applied in combination with MicroPulse to maximize the prompt effect of intravitreal pharmacotherapy with the duration of laser treatment.

**TABLE 1: TREATMENT PARAMETERS  
IRIDEX IQ 577 for Diabetic Macular Edema**

<b>Wavelength:</b>	<b>577 nm</b>
<b>Test Burn in CW Mode</b>	
	Performed in non-edematous area of the retina, outside the vascular arcade.
Spot size on slit lamp adapter:	100 µm
Contact lens:	Mainster focal grid (laser magnification: 1.05x)
Power:	Start at 100 mW and increase power in 50 mW increments (moving to adjacent locations) until a barely visible burn is achieved. (250 mW in this case)
Exposure duration:	100 ms
<b>Subthreshold Treatment in MicroPulse Mode</b>	
Spot size on slit lamp adapter:	100 µm
Contact lens:	Mainster focal grid: (1.05x)
Power:	2x power needed for test burn (500 mW in this case)
Exposure duration:	200 ms (delivering a train of 100 micropulses per application)
Duty cycle:	5%
Treatment pattern:	High density (confluent) grid over macular thickening
Endpoint:	Not visible – rely on objective post-treatment outcome measures (VA, OCT, FA)

Treatment techniques and opinions presented in this case report are those of the author. IRIDEX assumes no responsibility for patient treatment, outcome, or for physicians' negligence.

IRIDEX, IRIDEX logo are registered trademarks, and MicroPulse is a trademark of IRIDEX Corporation.