

Successful Treatment of DME with 577 nm MicroPulse™ Laser Therapy in an Otherwise Non-compliant Patient



Jonathan D. Walker, MD, practices with Allen County Retinal Surgeons in Fort Wayne, Ind., and is an assistant clinical professor at the Indiana University School of Medicine. In addition to his clinical practice, he works with local free clinics using telemedicine to identify

patients with diabetic retinopathy, and is also involved with projects in developing countries such as Nicaragua, Honduras and Fiji. Dr. Walker is the author of the book "Diabetic Retinopathy for the Comprehensive Ophthalmologist."

Evidence supporting the safety and effectiveness of MicroPulse Laser Therapy (MPLT) has been building for quite some time, and it stands in stark contrast to the conventional wisdom that retinal laser treatment cannot work unless it induces tissue-damaging burns. As such, MPLT is an interesting and exciting concept, which I began putting into practice 6 years ago. Frankly, I was initially somewhat surprised by its efficacy. From a safety perspective, it has lived up to my expectations.¹ Although I don't routinely repeat fluorescein angiography after MPLT and I do not use fundus autofluorescence, I've seen no signs of tissue damage in my MPLT patients. This, of course, is very different from the clinically apparent scarring in patients who've undergone traditional focal laser treatment, some of whom experience the visual effects indefinitely.

I have used MPLT to treat hundreds of patients, primarily for diabetic macular edema (DME) and macular edema secondary to branch retinal vein occlusion. I have achieved positive results in the majority of my DME cases, which is in line with what's been reported by others in the literature.²⁻⁵ It's been gratifying to use MPLT to help control this hard-to-manage disease without causing permanent scarring.

PATIENT HISTORY, PRESENTATION AND TREATMENT

Among the cases of DME I have treated with MPLT, one serves as a particularly realistic example of what can be accomplished. The patient was a 64-year-old white male who came to my practice from a free clinic that takes part in a telemedicine program. In October 2010, I treated diabetic retinopathy eccentric to the fovea in his left eye with thermal focal laser. The treated area stabilized, but 1 year later, he developed center-involved DME in the same eye. I recommended he regularly use a topical NSAID to help control the

edema, but he didn't comply. I also discussed anti-VEGF therapy with him, which we could likely have obtained through a manufacturer's patient assistance program because he was uninsured, but he didn't want to have any injections. MPLT was therefore the only remaining course of action.

In October 2011, the patient agreed to undergo MPLT for the center-involving DME in his left eye. His visual acuity was 20/70 and central subfield thickness (CST) as measured by spectral-domain optical coherence tomography (Spectralis, Heidelberg) was 341 μm (Figure 1). Prior to the treatment, I used the IRIDEX IQ 577™ laser in continuous-wave mode to perform a test burn away from the macula using a 100- μm spot and 150 ms duration. I titrated the power upward until I observed a barely visible tissue reaction, which occurred at 100 mW. For MPLT, I switched the laser to MicroPulse mode at a 5% duty cycle and doubled the power to 200 mW (Table 1). I delivered 622 spots confluent over the area of edema. Placing such a high number of spots would be difficult manually; however, with the IQ 577, it is possible to use a repeat setting of 10 ms, which makes the process efficient.

"From a safety perspective, [MPLT] has lived up to my expectations... I've seen no signs of tissue damage in my patients."

The patient returned to the office for his first follow-up 2 months later. The macular edema had decreased, and it continued to decrease over subsequent months. Although MPLT sometimes dramatically reduces edema quickly, it's not uncommon for the effects to occur more gradually, as they did in this case. At the patient's most recent visit in May of this year, 19 months after MPLT, his visual acuity was 20/40 despite an emerging cataract, and CST was within the normal range at 266 μm (Figure 2). I consider this a very good outcome given the fact that I was unable to use other treatments. MPLT can also be safely repeated, and I've treated patients more than once whenever edema warrants intervention.

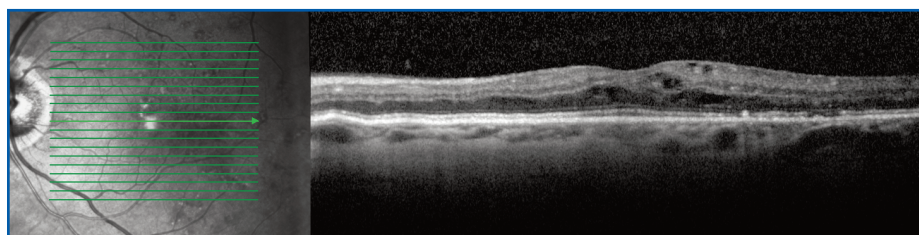


Figure 1. October 2011, left eye, prior to MPLT | CST 341 μm | VA 20/70.

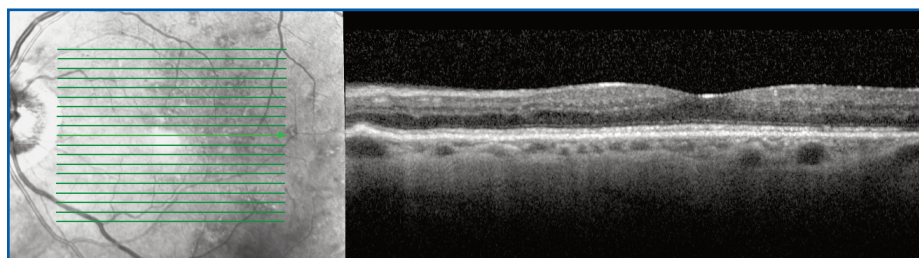


Figure 2. May 2013, left eye, 19 months post MPLT | CST 266 μm | VA 20/40 (with a developing cataract).

INCORPORATING MPLT INTO MY TREATMENT STRATEGIES

Had this particular patient been willing to undergo anti-VEGF injections, I likely would have provided them in conjunction with MPLT and possibly other treatments as well. I have found combination therapy to be most effective for DME. I tend to utilize whichever treatments are necessary for each patient, including topical NSAIDs, anti-VEGF agents, traditional focal laser when the anatomy calls for it, and MPLT — particularly when edema involves the fovea. Using all of the available options, I am able to minimize the treatment burden associated with each individual

TABLE 1. TREATMENT PARAMETERS

IRIDEX IQ 577 for diabetic macular edema

- Wavelength: 577 nm
- Spot size on slit lamp adapter: 100 μm
- Contact lens: Volk Area Centralis
- Power: 200 mW (based on 2x the power determined from a continuous wave test burn)
- Exposure duration: 150 ms
- Duty cycle: 5%
- MicroPulse delivery: high-density confluent application over the edematous area; 622 spots

modality. Logistically speaking, it is an advantage to be able to use the IQ 577 laser for several types of traditional treatments as well as MicroPulse. Although I have used the IRIDEX IQ 810™ laser with good results and the 810 nm wavelength allows safe treatments at higher duty cycles, the IQ 577 seems to be more comfortable for patients. For these reasons, I tend to use the IQ 577 more often.

If I had to summarize my experience with MPLT in just one sentence, I would say that I would find it difficult to treat my diabetic patients without it. ■

REFERENCES

1. Vujosevic S, Martini F, Convento E, et al. Subthreshold laser therapy for diabetic macular edema: metabolic and safety issues. *Curr Med Chem*. E-pub ahead of print, May 27, 2013.
2. Luttrull JK, Musch DC, Mainster MA. Subthreshold diode micropulse photocoagulation for the treatment of clinically significant diabetic macular oedema. *Br J Ophthalmol*. 2005;89(1):74-80.
3. Luttrull JK, Dorin G. Subthreshold diode micropulse laser photocoagulation (SDM) as invisible retinal phototherapy for diabetic macular edema: a review. *Curr Diabetes Rev*. 2012;8(4):274-284.
4. Lavinsky D, Cardillo JA, Melo LA Jr, Dare A, Farah ME, Belfort R Jr. Randomized clinical trial evaluating mETDRS versus normal or high-density micropulse photocoagulation for diabetic macular edema. *Invest Ophthalmol Vis Sci*. 2011;52(7):4314-4323.
5. Parodi MB, Spasse S, Iacono P, Di Stefano G, Canziani T, Ravalico G. Subthreshold grid laser treatment of macular edema secondary to branch retinal vein occlusion with micropulse infrared (810 nanometer) diode laser. *Ophthalmology*. 2006;113(12):2237-2242.

Treatment techniques and opinions presented in this case report are those of the author. IRIDEX assumes no responsibility for patient treatment and outcome. IRIDEX, IRIDEX logo are registered trademarks, and MicroPulse is a trademark of IRIDEX Corporation.