

## Prophylactic Treatment of Age-Related Maculopathy with 577-nm Subthreshold MicroPulse Laser

**Sergey Rykov, Prof.** is Director of the Eye Microsurgery Center in Kiev, Ukraine.

**Natalia Pasechnikova, Prof, MD, PhD,** is Director of Filatov's Eye Disease and Tissue Therapy Institute, Odessa, Ukraine.

**Sviatoslav Suk, MD, PhD,** is Chief of the Laser Unit at the Eye Microsurgery Center in Kiev, Ukraine. Contact him at +38067519889 or laser\_dep@mail.ru.

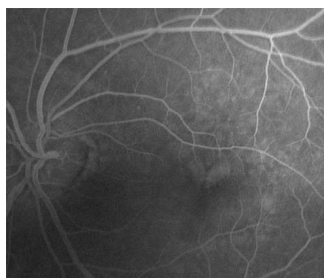
**Stanislav Saksonov, MD,** is an ophthalmologist at the Laser Unit in Kiev, Ukraine. Contact him at +380679199899 or s\_saksonov@mail.ru.

### History and examination

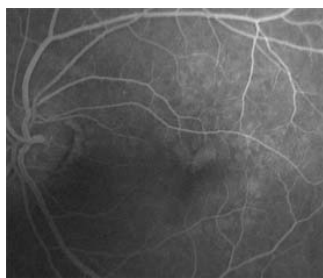
This case series includes 10 patients considered at high risk for progression to advanced age-related macular degeneration (AMD). All 10 had already been diagnosed with exudative (wet) AMD in one eye and displayed signs of age-related maculopathy (ARM) in the fellow eye. The patients ranged in age from 55 to 78 years old. Six were female and four were male.

On red-free fundus photographs, ARM was defined as the presence of more than 10 soft, yellow drusen, each ranging

Figure 1



FA before 577 nm MicroPulse laser treatment.



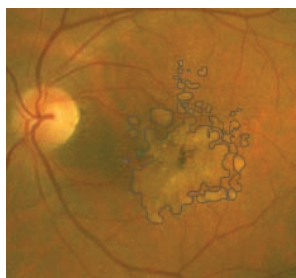
FA 15 min. after procedure. No laser burns identified.

from 63 to 250  $\mu\text{m}$  in greatest linear dimension. The pattern of drusen was scatter, subconfluent, or confluent. Drusen and focal hyperpigmentation were present within 2250  $\mu\text{m}$  of the foveal center. No leakage was detected by optical coherence tomography and fluorescein angiography (FA).

Pre-treatment mean visual acuity (VA) was 0.2 logMAR (20/32

Snellen). Threshold macular sensitivity was measured by Oculus TwinField 2 10° macular threshold test. FA was performed in order to exclude the presence of choroidal

Figure 2



Drusen manually defined to calculate approximate area of ARM changes.

neovascularization (CNV) and to determine the presence of threshold retinal pigment epithelium (RPE) damage after the procedure (Fig 1). The areas of drusen-induced RPE changes on color photo were identified and marked manually (Fig 2), and special software was used to determine the number of pixels. By estimating that the diameter of the peripapillary vein is 125  $\mu\text{m}$ , the mean diameter of the veins at the edge of the optic nerve in each eye was measured in pixels. The areas of drusen-induced RPE changes in pixels were converted to square millimeters using the mean diameter of veins at the edge of the optic nerve in each eye. The following equation was used to calculate the area: Area in  $\text{mm}^2$  = area in pixels X (0.125 mm/mean diameter of veins at the edge of optic nerve).<sup>1</sup> Mean retinal area affected by drusen-induced RPE changes was 2.7  $\text{mm}^2$  (range 2.08 – 4.23  $\text{mm}^2$ ).

### Treatment

All treatments were performed with the IQ 577™ yellow laser (IRIDEX, Mountain View, CA). Patients received treatment under topical anesthesia. To determine the laser treatment power, we first applied a test spot to the retina, nasal to the optic nerve, using the laser in its continuous-wave (CW) mode, with 200  $\mu\text{m}$  spot, 150 ms exposure duration, and titrating upward the power to produce a mild gray burn (powers ranged from 60 to 150 mW). To deliver subvisible, subthreshold treatment, we switched the laser to its MicroPulse™ mode, using a 15% duty cycle, doubled the power determined for the visible test burn, and maintained a 200  $\mu\text{m}$  spot and a 150 ms exposure duration.

We delivered the subthreshold MicroPulse laser treatment in a confluent pattern over the drusen (avoiding the area less than 500  $\mu\text{m}$  from the center of fovea) in the ARM eye of each patient. In each eye, 300-400 treatment spots were applied.

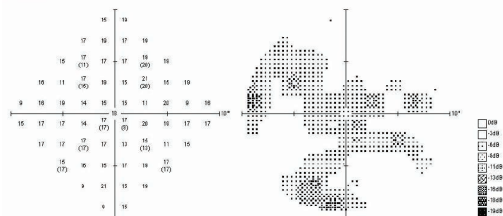
### Results

After 12 months of follow-up, partial resolution of macular drusen was obtained in 7 of the 10 eyes (70%). The mean decrease of drusen area (software calculated) on color photos was 0.92  $\text{mm}^2$  (34%,  $p < 0.05$ ). There were no visible signs of laser treatment on FA performed immediately after the treatment. (Fig 1). Mean VA (0.2 logMar; 20/32 Snellen) did not change. In one patient, VA worsened to 0.6 logMAR (20/80 Snellen) due to cataract progression; in another it improved significantly to 0.00 logMAR (20/20 Snellen). Threshold macular sensitivity remained stable or increased in 9 of 10 eyes (90%) (Fig 3). In one eye, it decreased due to progression of cataract. None of the 10 eyes has progressed to advanced or exudative AMD.

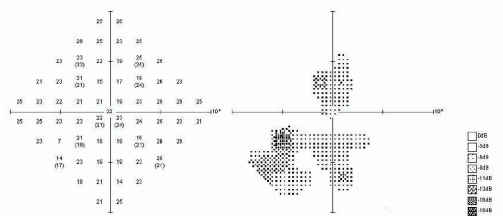
### Discussion and treatment pearls

Large confluent drusen in ARM are a risk factor for

Figure 3

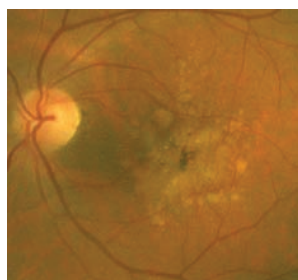
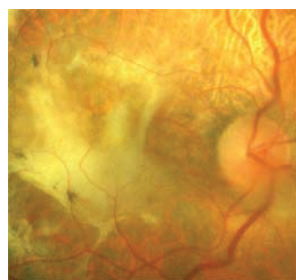


Threshold macular sensitivity 10° pre-treatment.



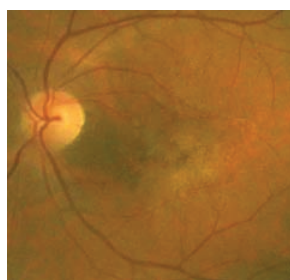
Threshold macular sensitivity 10° 12 months post-treatment.

Case Example



A 63-year-old male with AMD subretinal fibrosis VA 20/640 OD; VA of 20/40 ARM pre-treatment OS.

progression to exudative AMD.<sup>2-4</sup> The Macular Photocoagulation Study (MPS) demonstrated that CNV lesions in AMD are not the point for laser treatment.<sup>5,6</sup> Photodynamic therapy showed modest benefit.<sup>7</sup> Anti-vascular endothelial growth factor (anti-VEGF) therapy is the modern standard of care for exudative



VA 20/40 12 months post-treatment. Still no signs of laser treatment.

AMD but this involves a long course of treatment with multiple intravitreal injections, possible complications and frequent relapse of the exudative changes. Therefore, prophylactic treatment in patients with high-risk characteristic drusen has potential benefit in retaining visual function.

A 33% efficacy of CNV preventive treatment would reduce the rate of legal blindness caused by CNV by more than 50%.<sup>8</sup> Many investigators have studied prophylactic treatment with different treatment techniques.<sup>9</sup> There are two major multicenter randomized clinical trials: the Prophylactic Treatment of Age-related Macular Degeneration (PTAMD) study using subthreshold invisible diode laser photocoagulation<sup>10</sup> and the Complications of Age-related Macular Degeneration Prevention Trial (CAPT) using threshold visible burns.<sup>11</sup> Subthreshold treatment showed equivalent drusen reduction to threshold treatment, but the effect was a bit postponed, taking up to 6 months or longer to occur. At 12 months after treatment, 65.4% of subthreshold laser-treated eyes had a major drusen reduction, while 62.3% of threshold laser-treated eyes had a major drusen reduction 12 months after treatment.<sup>10</sup>

Modern laser technologies and recent protocols, such as MicroPulse and the 577 nm yellow wavelength, have already shown potential benefit in the treatment of macular diseases.<sup>12,13</sup> A 577 nm laser may offer advantages over other laser treatments. The highest absorption of laser light by oxyhemoglobin in the macula peaks at 577 nm, so one can use less power to greater effect, particularly in MicroPulse emission mode. In addition, the uptake of 577 nm light by the xanthophyll in the fovea is negligible, increasing safety when treating closer to the fovea. Additionally, in MicroPulse emission mode, the laser energy is delivered in envelopes of repetitive short pulses spaced apart to allow tissue to cool between pulses. This produces subtle thermal elevations that result in therapeutic effects without any visible laser-induced damage at any time post laser treatment.

Larger studies and longer follow-up are needed, but this case demonstrates that the 577 nm MicroPulse yellow laser may be useful in slowing or preventing the progression of AMD in high-risk eyes.

References

- Rodanant N, et al. Predictors of drusen reduction after subthreshold infrared (810 nm) diode laser macular grid photocoagulation for nonexudative age-related macular degeneration. *Am J Ophthalmol* 2002;134(4):577-85.
- Gass JD. Drusen and disciform macular detachment and degeneration. *Arch Ophthalmol* 1973;90(3):206-17.
- Bressler NM, et al. Five-year incidence and disappearance of drusen and retinal pigment epithelial abnormalities. Waterman study. *Arch Ophthalmol* 1995;113(3):301-8.
- Klein R, et al. The five-year incidence and progression of age-related maculopathy: The beaver dam eye study. *Ophthalmology* 1997;104(1):7-21.
- Moisseiev J, et al. The impact of the macular photocoagulation study results on the treatment of exudative age-related macular degeneration. *Arch Ophthalmol* 1995;113(2):185-9.
- Freund KB, et al. Age-related macular degeneration and choroidal neovascularization. *Am J Ophthalmol* 1993;115(6):786-91.
- Treatment of Age-related Macular Degeneration With Photodynamic Therapy Study Group. Photodynamic therapy of subfoveal choroidal neovascularization in age-related macular degeneration with verteporfin: One-year results of 2 randomized clinical trials—tap report 1. *Arch Ophthalmol* 1999;117(10):1329-1345.
- Lanchoney DM, et al. A model of the incidence and consequences of choroidal neovascularization secondary to age-related macular degeneration. Comparative effects of current treatment and potential prophylaxis on visual outcomes in high-risk patients. *Arch Ophthalmol* 1998;116(8):1045-52.
- Cleasby GW, et al. Prophylactic photocoagulation of the fellow eye in exudative senile maculopathy. A preliminary report. *Mod Probl Ophthalmol* 1979;20:141-7.
- Olk RJ, et al. Therapeutic benefits of infrared (810-nm) diode laser macular grid photocoagulation in prophylactic treatment of nonexudative age-related macular degeneration: Two-year results of a randomized pilot study. *Ophthalmology* 1999;106(11):2082-90.
- The complications of age-related macular degeneration prevention trial (CAPT): Rationale, design and methodology. *Clin Trials* 2004;1(1):91-107.
- Pasechnikova N, Suk S. 577 nm micropulse laser treatment of macular edema secondary to branch retinal vein occlusion. *Retina Today* 2011;Supplement (April):11-13.
- Peroni R, et al. A combined low energy, short pulsed 577 nm mild macular grid photocoagulation with 577 nm-micropulsed central laser stimulation for diabetic macular edema with foveal leakage (the sandwich grid). *Invest. Ophthalmol. Vis. Sci.* 2011;52(6):590-