

MicroPulse® as First-line Monotherapy for DME: Efficacy at Considerable Cost Savings



Ezio Cappello, MD, is director of the Medical Retina Unit at City Hospital in Bassano Del Grappa, Vicenza, Italy.



Simonetta Morselli, MD, is chief of the Ophthalmic Unit at City Hospital in Bassano Del Grappa, Vicenza, Italy.

In 2013 when we began using the IRIDEX IQ 577™ yellow laser to provide MicroPulse laser therapy in our hospital's retina unit, we expected we would mainly utilize it as an alternative for patients who weren't good candidates for intravitreal injections or didn't want to receive them. For instance, we recommended anti-VEGF therapy for a monocular patient who developed diabetic macular edema (DME) in his sighted eye, with central macular thickness (CMT) of 410 μm , and visual acuity (VA) of 20/100. He categorically refused, so we treated him with MicroPulse. During a 3-year period, he received

three MicroPulse treatments and no anti-VEGF injections, and he's doing very well with 20/50 VA and stable retinal thickness.

Since those early days, our use of MicroPulse has greatly expanded. We now offer this option as first-line monotherapy to all patients with DME who have an intact retinal pigment epithelium, good VA¹ or moderate vision loss, CMT less than 500 μm ,² no vitreoretinal traction, and no macular ischemia. (Note: 400 μm is a more common threshold, but we have patients with 400-500 μm CMT who refuse intravitreal injections, and we have found MicroPulse to be effective up to 500 μm .) We do not limit the option of MicroPulse for first-line treatment to patients with non-center-involving edema.³ Although we avoided transfoveal application when we first performed MicroPulse, as our experience grew, we realized that we never observed any laser damage. As such, we now treat transfoveally with confidence. Also, we inform

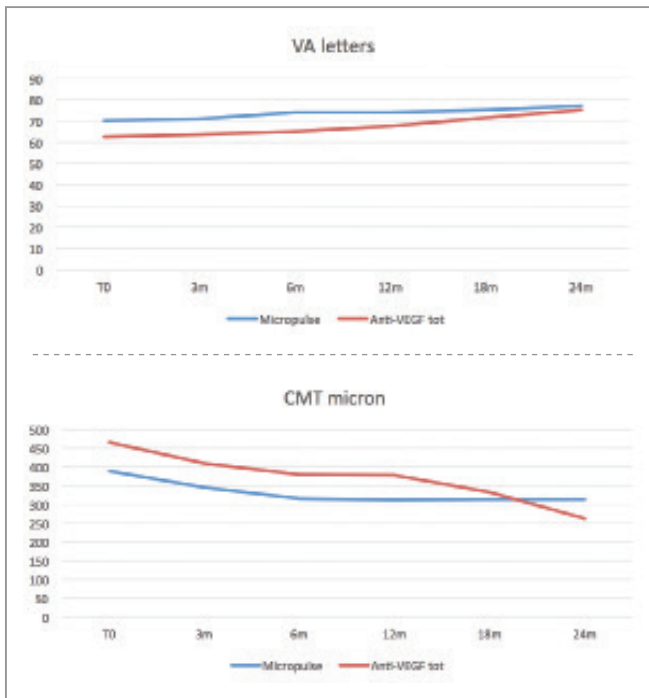


Figure 1. Using our DME treatment protocol, we achieve similarly positive anatomic and functional outcomes in patients treated with MicroPulse monotherapy versus patients treated with anti-VEGF injections or a combination of the two.

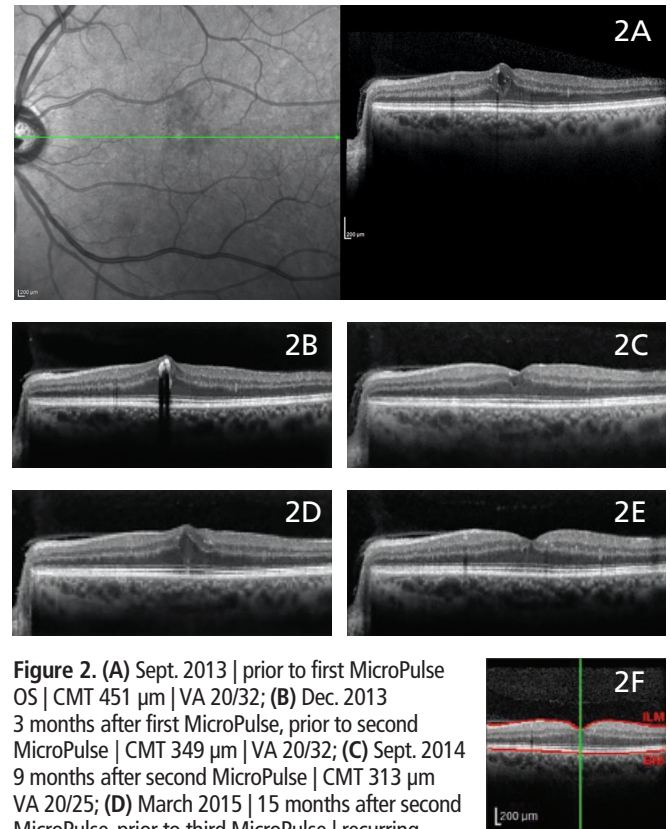


Figure 2. (A) Sept. 2013 | prior to first MicroPulse OS | CMT 451 μm | VA 20/32; (B) Dec. 2013 | 3 months after first MicroPulse, prior to second MicroPulse | CMT 349 μm | VA 20/32; (C) Sept. 2014 | 9 months after second MicroPulse | CMT 313 μm | VA 20/25; (D) March 2015 | 15 months after second MicroPulse, prior to third MicroPulse | recurring edema | VA 20/25-2; (E) Sept. 2015 | 6 months after third MicroPulse | CMT 275 μm | VA 20/20-1; (F) March 4, 2016 | 2 years and 7 months after first MicroPulse | CMT 274 μm | VA 20/20-1.

patients that anti-VEGF therapy is typically used first for their condition and that if MicroPulse isn't effective, they can switch to an anti-VEGF or a combination of the two therapies. When we present these options side-by-side, about half of our patients choose to begin treatment with MicroPulse. Per our protocol, if a patient is stable or improved 3 months after the first MicroPulse treatment, we usually won't treat him at that visit. If VA or CMT is worse at the 3-month follow-up, we re-treat again with MicroPulse. Usually, if VA becomes worse than 20/50 at any point, we add or shift to anti-VEGF treatment.

MICROPULSE BENEFITS PATIENTS AND HOSPITAL

Tracking our data, we've learned that our MicroPulse for DME protocol has resulted in similar favorable outcomes for both MicroPulse monotherapy patients and those who either began with anti-VEGF monotherapy or were switched from MicroPulse monotherapy to anti-VEGF treatment or a combination of both (Figure 1). Interestingly, replacing anti-VEGF injections with MicroPulse for first-line monotherapy when appropriate has allowed our ophthalmology unit to save more than €200,000 per year. As you would imagine, we can put the savings to good use in other segments of our budget. We also have used MicroPulse as first-line monotherapy for central serous chorioretinopathy, and our early results are encouraging.

Table 1. TREATMENT PARAMETERS

IRIDEX IQ 577 Laser with MicroPulse as first-line monotherapy for center-involving DME

- Wavelength: 577 nm
- Spot size on slit lamp adapter: 100 µm
- Contact lens: Single-use Retina 90 [Katena, SMT 005 (K30-1320)] (1.0x Laser Spot Magnification)
- Power: 250 mW
- Exposure duration: 200 ms
- Duty cycle: 5%
- MicroPulse Delivery: 500-800 confluent spots (high density) targeted to thickened area of the retina, including the fovea

“Overall, we’re pleased with the functional and anatomic results that we can achieve with MicroPulse laser monotherapy for center-involving DME in carefully selected patients. As an added bonus, the treatment enables significant cost savings and reduces the often-heavy treatment burden on patients.”

A CASE THAT REPRESENTS OUR DME PROTOCOL

A 64-year-old male, diagnosed with diabetes in 1993, presented with DME in September 2013. His VA was 20/32, his CMT was 451 µm (Figure 2A), and he received his first MicroPulse treatment (Table 1).

At his first follow-up visit 3 months later (Figure 2B), we performed a second MicroPulse treatment because his VA remained the same and the edema had only improved to 349 µm. When the patient returned 6 months after the second MicroPulse treatment, his VA was stable and additional CMT improvement was observed, so we didn't treat him but we scheduled a 3-month follow-up. In September 2014, 9 months after the second MicroPulse, CMT was improved to 313 µm and VA increased from 20/32 to 20/25 (Figure 2C). We next saw the patient in March 2015, 15 months after his second MicroPulse. DME had begun to recur and VA dropped slightly to 20/25-2 (Figure 2D). We treated him that day with MicroPulse. In September 2015, 6 months after the third MicroPulse treatment, retinal anatomy had returned to nearly normal, CMT was 275 µm, and VA measured 20/20-1 — a very good outcome (Figure 2E). At the patient's most recent visit in March 2016, the treated eye remained stable with 274 µm CMT and 20/20-1 VA (Figure 2F).

Overall, we're pleased with the functional and anatomic results — with no iatrogenic effects — that we can achieve with MicroPulse laser monotherapy for center-involving DME in carefully selected patients. As an added bonus, the treatment enables significant cost savings and reduces the often-heavy treatment burden on patients. ■

REFERENCES

1. Luttrull JK, et al. *Retina*. 2014;34(10):2010-2020.
2. Mansouri A, et al. *Eye (Lond)*. 2014;28(12):1418-1424.
3. Vujosevic S, et al. *Retina*. 2015;35(8):1594-1603.

Treatment techniques and opinions presented in this case report are those of the author. IRIDEX lasers are cleared for retinal photocoagulation of vascular and structural abnormalities of the retina and choroid; and iridotomy, iridectomy and trabeculoplasty in angle-closure glaucoma and open-angle glaucoma. IRIDEX assumes no responsibility for patient treatment and outcome. IRIDEX, IRIDEX logo, and MicroPulse are registered trademarks, and IQ 577 is a trademark of IRIDEX Corporation.

IRIDEX | 1212 Terra Bella Avenue | Mountain View, CA 94043 | 800.388.4747 (U.S. inquiries) | info@iridex.com (U.S. & int'l inquiries) | www.iridex.com

© 2016 IRIDEX Corporation. All rights reserved. LT0646