

Micropulse Trans-scleral Cyclophotocoagulation for the Treatment of Glaucoma



AT Nguyen,¹ RJ Noecker^{1,2}
¹Department of Ophthalmology and Visual Science, Yale School of Medicine, New Haven, CT
²Ophthalmic Consultants of Connecticut, Fairfield, CT



Purpose

- To evaluate the safety and efficacy of micropulse trans-scleral cyclophotocoagulation (TSCPC) for the treatment of glaucoma.

Introduction

- TSCPC is a method of treating glaucoma that involves cycloablation of the ciliary body epithelium. The posited consequence of cycloablation is decreased aqueous humor production by the ciliary body with subsequent lowering of the intraocular pressure (IOP).¹
- The precise mechanism of IOP lowering has not yet been entirely elucidated but may also involve an increase in uveoscleral outflow. Cycloablative procedures have traditionally been reserved for refractory cases of glaucoma given its commonly associated adverse events, which include decreased vision and intraocular inflammation.^{1,2}
- Micropulse TSCPC, in contrast to continuous wave TSCPC, is a relatively new modality of cycloablation that applies pulsed treatments, which may minimize thermal injury to collateral tissues.^{3,4}

Methods

- Design:** Retrospective cohort study – the charts of 95 consecutive glaucoma patients that received micropulse TSCPC were reviewed.
- Treatment Protocol:** Patients were administered a retrobulbar block and treated with the Micropulse P3 device (Iridex IQ810 Laser Systems, CA) at 2.0-2.5 Watts with a duration of 90 seconds per hemisphere at a 31.3% duty cycle. If retreatment was needed, the same treatment parameters were used with an increase in power up to 3.0 Watts.
- Follow-up:** Patients were given topical corticosteroids in the operative eye post-procedurally with a one month taper. IOP-lowering medications with withdrawn as appropriate. Patients were seen on post-operative day 1, post-operative week 1, and post-operative months 1, 3, 6 and 12. All patients had follow-up for at least 1 year.
- Outcome measures:**
 - Post-operative IOP
 - Mean number of post-operative IOP medications

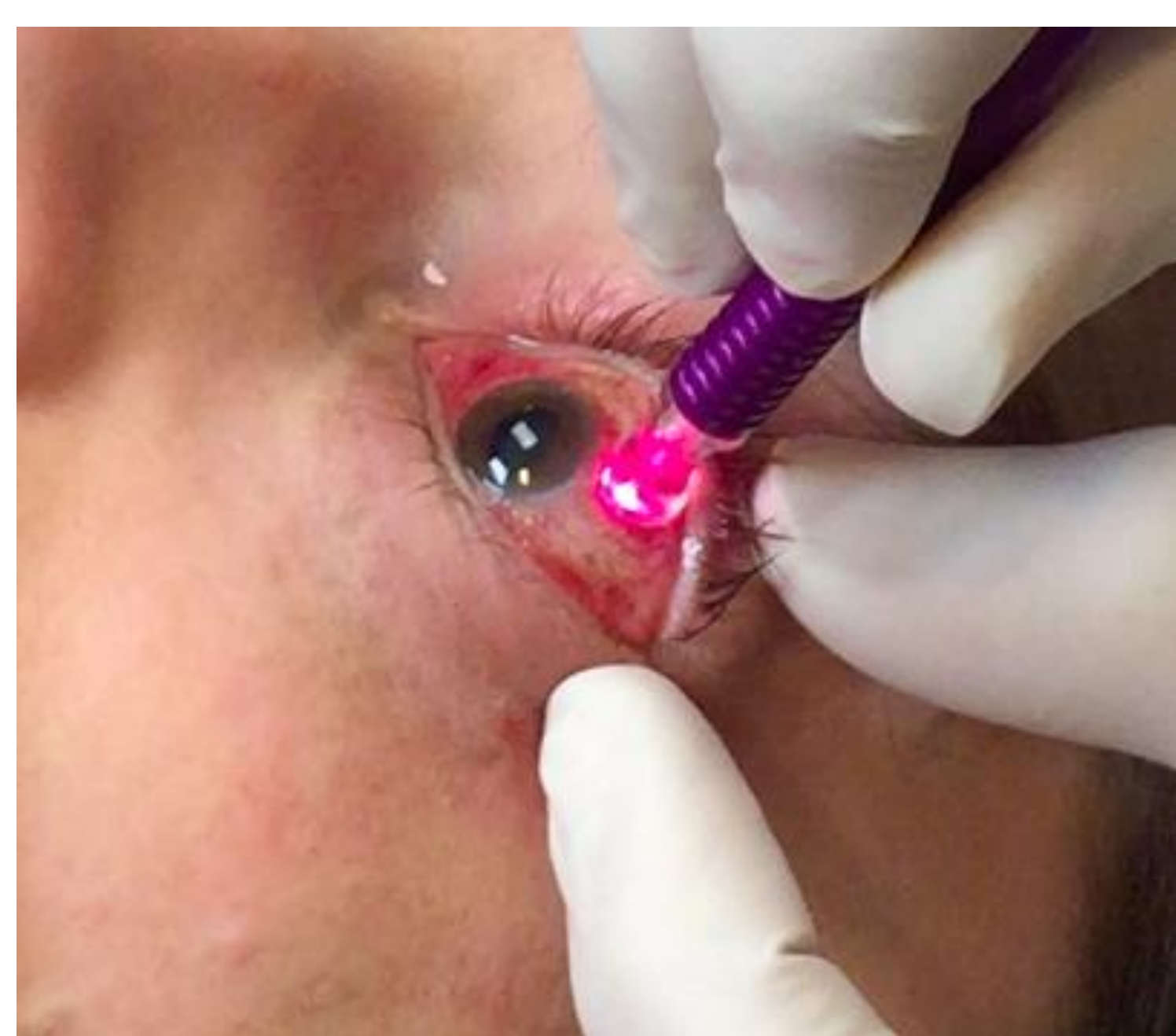


Figure 1. Typical Micropulse treatment.

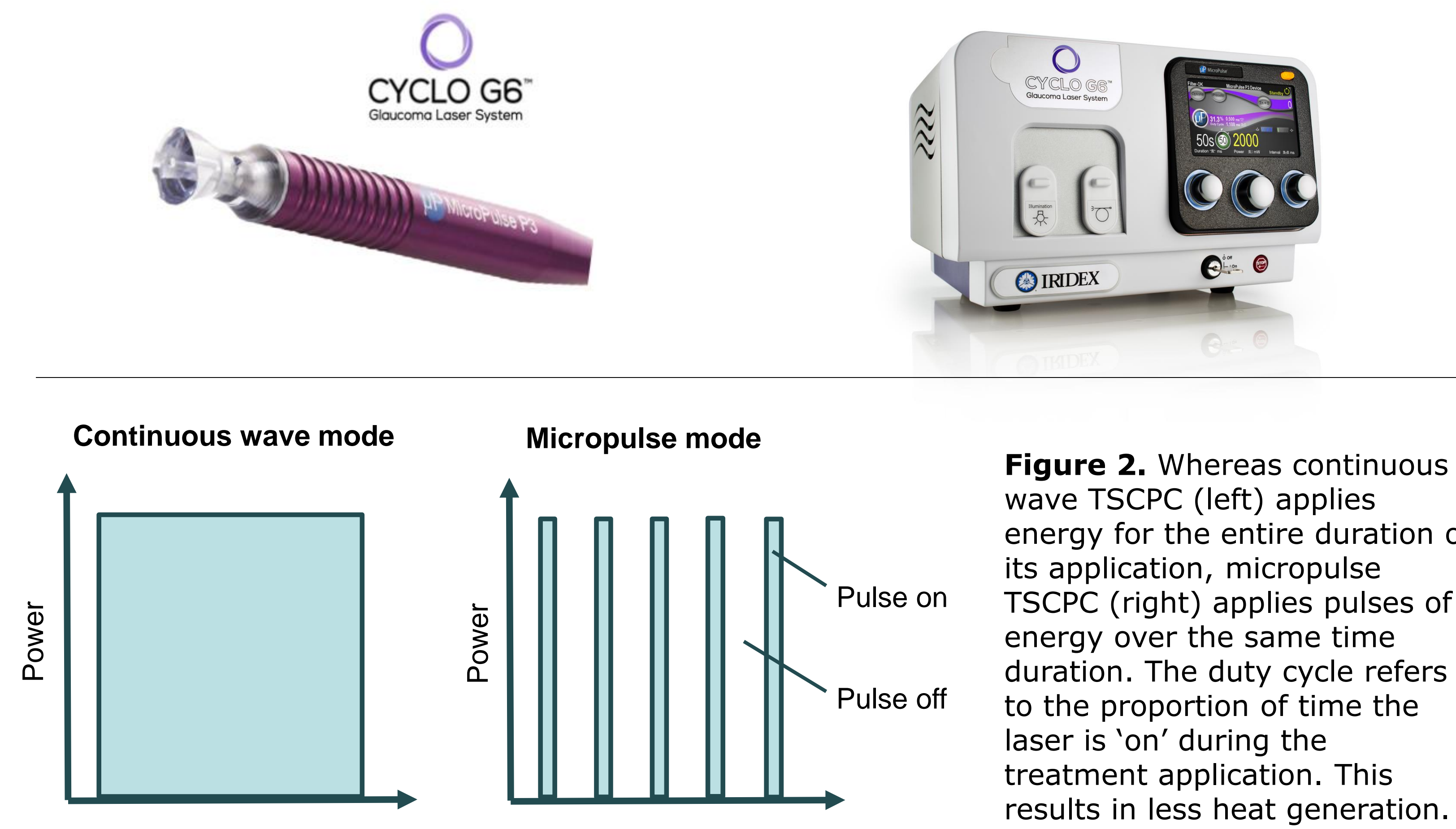


Figure 2. Whereas continuous wave TSCPC (left) applies energy for the entire duration of its application, micropulse TSCPC (right) applies pulses of energy over the same time duration. The duty cycle refers to the proportion of time the laser is 'on' during the treatment application. This results in less heat generation.

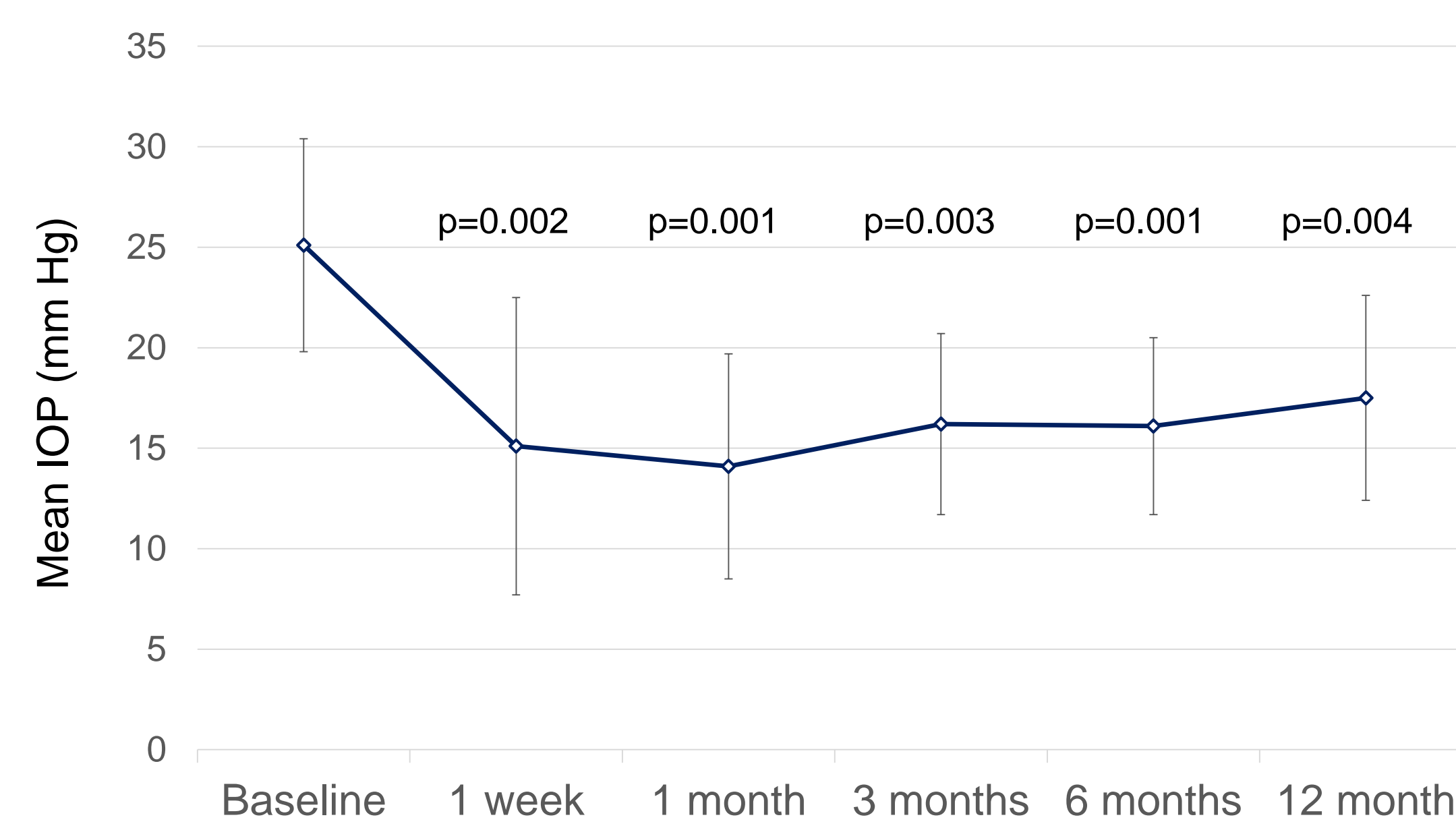


Figure 3. Mean IOP of patients with glaucoma treated with micropulse TSCPC at various post-procedural time points. The mean pre-operative IOP was 25.1 ± 5.3 mm Hg. The mean IOP was significantly different from the pre-treatment baseline value at all time points post-treatment. Error bars represent standard deviation.

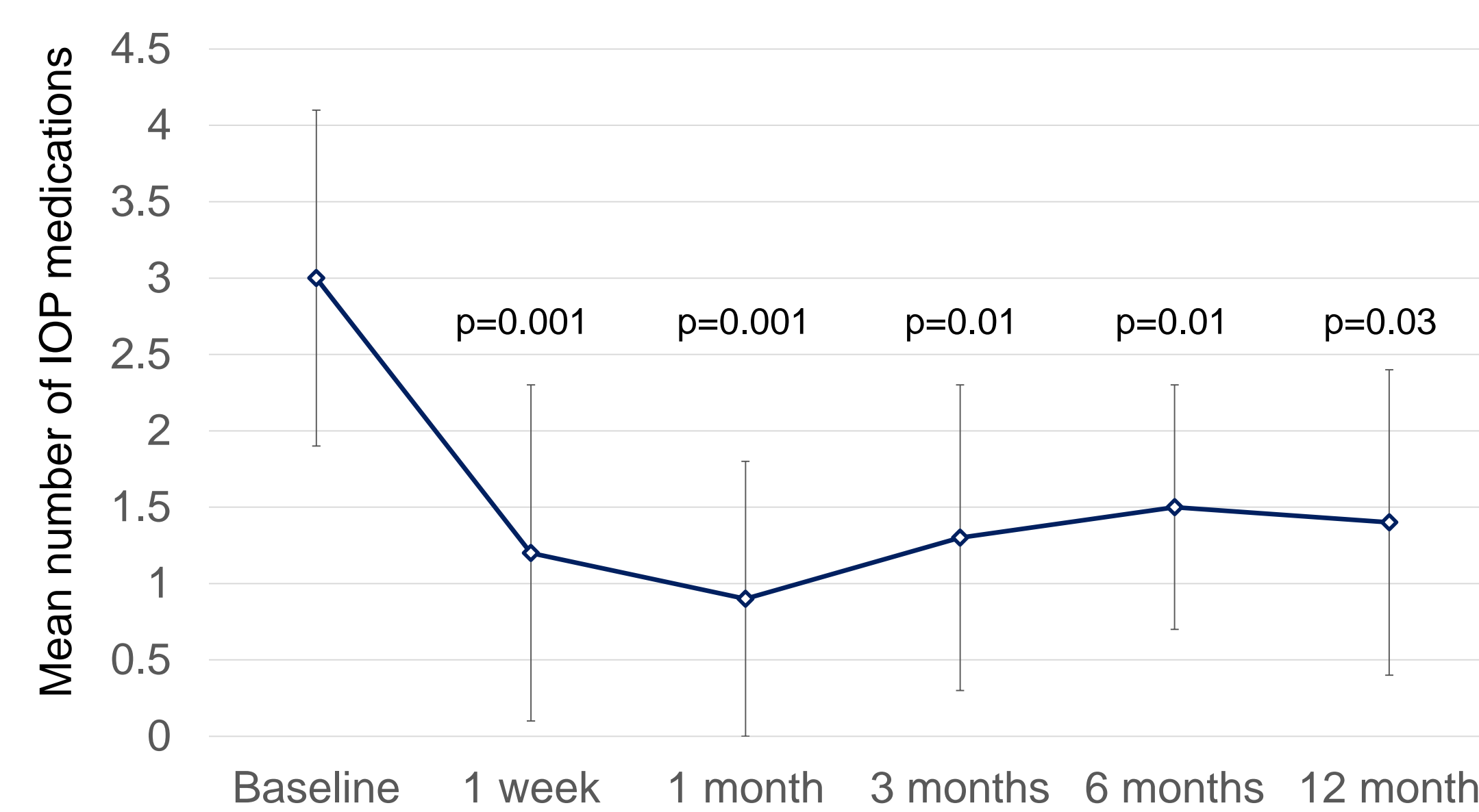


Figure 4. Mean number of topical IOP-lowering medications patients used by patients with glaucoma pre- and post-treatment with micropulse TSCPC. The average number of IOP-lowering medications pre-treatment was 3.0 ± 1.1. Treatment reduced the number of medications needed to control IOP at all post-procedural time points. Error bars represent standard deviation.

Demographics	
Age	69.2 years (range 16-95)
Gender	
Male	38
Female	57
Ethnicity	
African descent	15
Caucasian	53
Hispanic	27
Asian	0

Table 1. Demographic breakdown of patients with glaucoma treated with micropulse TSCPC.

Complications	Number of patients
Posterior synechiae	1
Hyphema	6
Persistent mydriasis	3
Choroidal effusion	3
Keratopathy	10
Suprachoroidal hemorrhage	0
Retinal detachment	0
Transient hypotony (IOP < 10)	10
Transient hypotony (IOP < 5)	1
Long-term hypotony	0
Persistent iritis	0

Table 2. Complications following micropulse TSCPC treatment in patients with glaucoma after 1 year of follow-up.

Results

- The study examined 95 eyes of 95 patients with glaucoma. The glaucoma subtypes treated included primary open-angle glaucoma (n=51), exfoliation glaucoma (n=24), chronic angle closure glaucoma (n=15), and congenital/juvenile glaucoma (n=5).
- The mean pre-operative IOP was 25.1 ± 5.3 mm Hg and the mean post-operative IOP at 12 months was 17.5 ± 5.1 mm Hg (p=0.004).
- The mean number of IOP-lowering medications used preoperatively was 3.0 ± 1.1; the mean number of medications used at the 12 month post-operative visit was 1.4 ± 1.0 (p=0.03).
- 22 patients received at least one retreatment with an increase in energy used; 8 patients had 3 rounds of treatment, 4 patients had 4 rounds of treatment, and 1 patient had 5 rounds of treatment.

Discussion

- Micropulse TSCPC may be a safe and effective treatment for glaucoma.
- Although TSCPC has traditionally been reserved for cases of refractory glaucoma or for patients with poor visual potential, the safety profile of micropulse TSCPC may expand the indications for cycloablation.^{3,4}
- Histopathologic examinations of human autopsy eyes treated with continuous wave TSCPC show architectural damage to collateral structures including the pigmented ciliary body epithelium, pars plana and iris stroma. Because of this, treated eyes may develop phthisis, hypotony and recalcitrant inflammation.⁵
- Expectedly, histopathologic studies on autopsy eyes treated with micropulse TSCPC exhibit less architectural destruction to the tissues surrounding the non-pigmented ciliary body epithelium (unpublished data). No cases of long-term hypotony were noted in treated eyes, a result which is shared by others investigators using micropulse TSCPC.^{3,4}
- Although micropulse CPC applies a gentler application of laser, the treatment remains efficacious at lowering IOP.
- The mean pre-operative IOP in our study was much lower than that of a previous investigation using micropulse TSCPC,⁴ suggesting that it can be utilized earlier than where traditional algorithms may place it.

References

- Guptha N, Weinreb RN. J Glaucoma 1997; 6:426-9.
- Kosoko O, Gasterland DE, Pollack IP, Enger CL. Ophthalmology 1996; 103:1294-302.
- Kuchar S, Moster MR, Reamer CB, Waisbourd M. Lasers Med Sci 2016; 31:393-6.
- Tan AM, Chockalingam M, Aquino MC, Lim Z, See J, Chew Paul TK. Clin Experiment Ophthalmol 2010; 38:266-72.
- Pantcheva MB, Kahook MY, Schuman JS, Rubin MW, Noecker RJ. Clin Experiment Ophthalmol 2007; 35:270-4.

Supported in part by an unrestricted departmental grant from Research to Prevent Blindness (RPB), Inc.